

## TAMBAQUI DEATH (*Colossoma macropomum*) BY HELMINTHS IN MARAJÓ ISLAND, PARÁ, BRAZIL

(Mortalidade de tambaqui, *Colossoma macropomum*, por  
helmintos na Ilha do Marajó, Pará, Brasil)

Tiago Paixão MANGAS\*; Fabricio Nilo Lima da SILVA;  
Luã Caldas de OLIVEIRA; Lenilton Alex de Araujo OLIVEIRA

Federal Institute of Education, Science and Technology of Pará (IFPA), *Campus Breves*.  
Antônio Fulgêncio da Silva Street, s/n, University Park, Breves, PA, Brazil.  
CEP: 68.800-000. \*E-mail: [tiago.mangas@ifpa.edu.br](mailto:tiago.mangas@ifpa.edu.br)

### ABSTRACT

In the Marajó Island (State of Pará, Brazil) the most bred species with the greatest economic interest is the tambaqui (*Colossoma macropomum*). Currently, one of the problem that most worries technicians and aquaculturists in Marajó is the occurrence of diseases. Many diseases require preventive management practices. However, such care is not always taken. Thus, the aim of this study was to report a case of tambaqui fingerling mortality by monogenous parasites in Marajó island. The animals were acquired in commercial fish farming and transported to the Federal Institute of Education, Science and Technology of Pará (IFPA) *Campus Breves*. A Part of fish were kept in laboratory for nutrition experiment and part was kept in excavated tanks. In conclusion, the occurrence of monogenoids resulted in mortality and reduced weight gain of animals kept in experimental environment, the same not being observed in their counterparts kept in excavated tanks.

**Keywords:** Amazon, aquaculture, performance, parasite.

### RESUMO

Na Ilha do Marajó (Estado do Pará, Brasil) a espécie mais criada e que apresenta o maior interesse econômico é o tambaqui (*Colossoma macropomum*). Atualmente, uma das questões que mais preocupam os técnicos e aquicultores no Marajó é a ocorrência de doenças. Muitas das enfermidades requerem práticas de manejo preventivas. Porém, nem sempre são tomados esses cuidados. Assim, o objetivo desse estudo foi relatar um caso de mortalidade de alevinos de tambaqui por parasitos monogenóides na ilha do Marajó. Os animais foram adquiridos em piscicultura comercial e transportados para o Instituto Federal de Educação, Ciência e Tecnologia do Pará (IFPA) *Campus Breves*. Parte dos peixes foram mantidos em laboratório para experimento de nutrição e outra parte foi mantida em viveiros escavados. Em conclusão, a ocorrência por monogenóides resultou em mortalidade e redução do ganho de peso dos animais mantidos em ambiente experimental, o mesmo não sendo observado nos seus congêneres mantidos em viveiros escavados.

**Palavras-chave:** Amazônia, aquicultura, desempenho, parasita.

### INTRODUCTION

Aquaculture continues to grow worldwide faster than other major food producing sectors. With the increase in the number of aquaculture enterprises in Brazil associated with

\*Endereço para correspondência:  
[fabricio\\_nilo@hotmail.com](mailto:fabricio_nilo@hotmail.com)

the intensification of production, there are outbreaks and high mortality of fish due to diseases. Thus, the equilibrium threshold among pathogens, environment and host can be easily broken (VELASCO *et al.*, 2019).

The most commonly produced native fish in the aquaculture of Marajó Island (Pará State, Brazil) is the tambaqui, *Colossoma macropomum* Cuvier, 1818 (Characiformes: Characidae). Mainly due to the availability of fingerlings throughout the year, due to the complete understanding of their artificial reproduction, growth potential, high productivity, rusticity and acceptance of captive feed. In tambaqui, there is a record of occurrence of several parasites with pathogenic potential. Among these parasites we can highlight the monogenous helminths (CHAGAS *et al.*, 2012).

Helminths of the Monogenoid class, also called monogenoids, are elongated and flat in shape, are mostly hermaphroditic, measuring approximately 400 to 800 micrometers in length and are provided with marginal hooks or anchors at the posterior end of the body, sometimes suckers at the anterior end. They parasites integument, fins, nasal cavities and mainly fish gills (IBAMA, 2006). Monogenoids cause a series of reactions and may result in mucus hypersecretion, which could lead to death by asphyxiation, or cause injuries facilitating the penetration of secondary agents, representing one of the limiting factors for fish production (CHAGAS *et al.*, 2012). Thus, the objective of this study was to report a case of monogenoid-parasitized tambaqui death in Marajó Island, Pará, Brazil.

## METHODOLOGY

### Study area

The study was conducted at the Natural Resources Laboratory (LRN) from the Federal Institute of Education, Science and Technology of Pará (IFPA), located in the municipality of Breves, Marajó Island, Pará, Brazil.

Twenty *Colossoma macropomum* fingerlings found dead or near death were necropsied. These animals were part of the project entitled “Study of the profile of fish farming in the municipality of Breves/Pará as a practice of rural extension in the Marajoara Amazon”. The animals were acquired in the municipality of Castanhal, northeastern Pará, and transported to Breves. Some of the animals were kept under laboratory conditions for a nutrition experiment and some were kept in three excavated tanks in the Aquaculture Sector.

### Methods of data collection

Mortality was observed in the samples of the experiment, which consisted of the administration of three diets, one alternative and two commercial ones presenting raw protein contents of 28% and 36%, respectively, during 60 days of culture. The fish were kept in nine 60-liter plastic boxes. The experiment protocol included daily water change as well as chemical and physical analysis. Periodic biometrics were performed. At least one specimen from each box was necropsied. For comparison, three specimens from one of the tanks were necropsied.

The necropsy procedure used is in accordance with Yanong (2003). In summary: Biometric data (total length and weight) were collected, followed by external inspection (body, head, fins, opercules, gills, eyes and oral cavity). Mucus scraping, gill biopsy and fins were then performed. After that, the abdominal cavity was opened for inspection of the internal organs. The categorization of parasitism in the gills was based on the work carried out by IBAMA (2006) where: the observation of one to five parasites by gill smear was considered normal; six to ten mild infection; and more than ten serious infections. Due to the size of the animals it was not possible to define the sex.

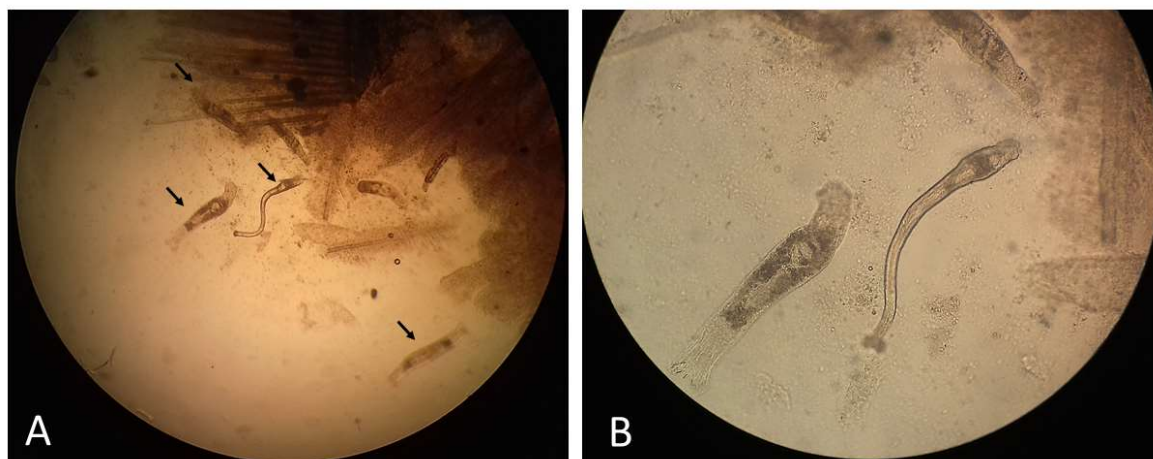
### Statistical analysis

The parasite prevalence data were calculated according to Velasco *et al.* (2019).

## RESULTS AND DISCUSSION

The average values of the water parameters of the experiment and the tanks analyzed were: pH  $7.4\pm 0.2$  and  $7.7\pm 0.1$ ; dissolved oxygen  $5.5\pm 2.4$  and  $5.8\pm 0.1$  mg.L<sup>-1</sup>; water temperature of  $26.1\pm 1.0$  and  $29.3\pm 1.6$  °C; and electrical conductivity of  $781.0\pm 542.5$  and  $806.1\pm 581.3$   $\mu\text{s.cm}^{-1}$ , respectively. All monitored water variables remained within limits established as satisfactory for the cultivation of tropical freshwater fish.

Of the 20 necropsied specimens, 12 were highly parasitized with monogenoids (Fig. 01, A and B) and 08 were in an advanced state of internal decomposition, which may have interfered with parasite observation (Tab. 01).



**Figure 01:** Microscopic image of monogenoids in tambaqui gills: A) Several monogenoids observed in tambaqui gills. 40x increase. B) Details of monogenoids at 100x magnification.

Prevalences of monogenoid infection in tambaqui gills are quite varied in the scientific literature: SANTOS *et al.* (2018) report a 91% prevalence of monogenoids in tambaqui juveniles, in a study conducted in the state of Sergipe; However, SOBERON *et al.* (2014) observed 27.8% of parasitism in tambaquis farmed on a property in Peru.

**Table 01:** Result of necropsies of tambaqui fingerlings (*Colossoma macropomum*) in Breves, Marajó Island, Brazil.

Specimens	n	Parasite (%)	Location of parasite	Biopsy parasite
Experiment	20	13 (65)	Gill	>10
Fishpond	3	3 (100)	Gill	3-9

In the tank samples that were necropsied, the presence of monogenoids was also observed, however, no visible signs of disease or deficiency were observed and the biometric data were superior to those of the experimental animals (Fig. 02, A and B). SOBERON *et al.* (2014) report a small increase in the blood glucose levels of tambaquis parasitized by *Anacanthorus spathulatus* Kritsky, Thatcher & Kayton, 1979, which can be an important indicator in the production of hormones such as cortisol and adrenaline related to stress in fish captivity. However, the authors did not observe any signs of physiological alteration in the fish. They state, agreeing with GODOI *et al.* (2012), which that good breeding management is essential for the control of parasites, since, present in low quantities, they are not able to interfere in the health of the fish. Changes in blood glucose level were also observed in the work of ROCHA *et al.* (2018).



**Figure 02:** A) Experimental specimen. Note the low growth when compared to the same age specimen kept in the excavated nursery. B) specimen kept in excavated nursery.

In the present study, there were no signs of stress in animals farmed at tanks although the infestation was considered high (mean >6 monogenoids per slide), in disagreement with the report of IBAMA (2006). However, this was similar to that reported by MARENGONI *et al.* (2009) who observed high parasitism intensity in Nile tilapia (*Oreochromis niloticus*), but no apparent disturbance in fish. These authors state that low parasite infestations may also be responsible for mortality as long as water quality and dissolved oxygen decline. This may be the cause of mortality observed in our experiment, once with the presence of the parasite the animals kept in the tanks showed no deaths.

SANCHES *et al.* (2007), report the mortality of Pampo fish fingerlings *Trachinotus carolinus* (Linnaeus, 1766), captured from the natural environment and submitted to high density cultivation, with high monogenous infestation in gill. Symptoms of apathy, discoloration and weight gain deficiency observed by these authors were also noted in our research.

### FINAL CONSIDERATIONS

In conclusion, the high monogenous infestation resulted in mortality and reduced weight gain in tambaqui fingerlings kept in an experimental environment, which was not observed in their counterparts kept in excavated nurseries.

### ACKNOWLEDGMENTS

To the Dean of Extension and External Relations (PROEX) from the Federal Institute of Education, Science and Technology of Pará (IFPA), for the funding of the research (Notice No. 03/2016). To the fellows, volunteers, technicians and teachers involved in the “Marajoara Pisciculture Project” of IFPA *Campus Breves*.

### REFERENCES

- CHAGAS, E.C.; ARAÚJO, L.D.; GOMES, L.C.; MALTA, J.C.O.; VARELLA, A.M.B. Efeito do cloreto de sódio sobre as respostas fisiológicas e controle de helmintos monogenóides em tambaqui (*Colossoma macropomum*). *Acta Amazonica*, v.42, n.3, p.439-444, 2012.
- GODOI, M.M.I.M.; ENGRACIA, V.; LIZAMA, M.L.A.P.; TAKEMOTO, R.M. Relação parasito-hospedeiro tambaqui (*Colossoma macropomum* Cuvier 1818) e ectoparasitos coletados em pisciculturas do município de Rolim de Moura, no estado de Rondônia, Amazônia Ocidental, Brasil. *Acta Amazônica*, v.42, n.4, p.515-524, 2012.
- IBAMA. Pesquisas patológicas e genéticas em recursos pesqueiros da Bacia do Alto Paraguai / Centro de Pesquisa e Gestão de Recursos Pesqueiros Continentais. – Pirassununga: Ibama, 2006. 169p.
- MARENGONI, N.G.; SANTOS, R.S.; GONÇALVES JÚNIOR, A.C.; GINO, D.M.; ZERBINATTI, D.C.P.; LIMA, F.S. Monogenoidea (Dactylogyridae) em tilápias-do-Nilo cultivadas sob diferentes densidades de estocagem em tanques-rede. *Arquivo Brasileiro de Medicina Veterinária e Zootecnia*, v.61, n.2, p.393-400, 2009.
- ROCHA M.J.S.; JERÔNIMO, G.T.; COSTA, O.T.F.; MALTA, J.C.O.; MARTINS, M.L.; MACIEL, P.O.; CHAGAS, E.C. Changes in hematological and biochemical parameters of tambaqui (*Colossoma macropomum*) parasitized by metazoan species. *Revista Brasileira de Parasitologia Veterinária*, v.27, n.4, p.488-494, 2018.
- SANCHES, E.G.; OSTINI, S.; RODRIGUES, V.C.S. Ocorrência e tratamento de monogenóides em alevinos de Pampo (*Trachinotus carolinus*) cultivados

experimentalmente na região norte do estado de São Paulo. Revista Brasileira de Parasitologia Veterinária, v.16, n.1, p.1-4, 2007.

SANTOS, M.A.; PEIXOTO, J.S.; MADI, R.R.; ESPÓSITO, T.S. Protozoan and metazoan parasites of juvenile tambaqui *Colossoma macropomum* farmed in the Lower São Francisco, Brazil. Acta of Fisheries and Aquatic Resources, v.6, n.1, p.29-34, 2018.

SOBERON, L.; MATHEWS, P.; MALHERIOS, A. Hematological parameters of *Colossoma macropomum* naturally parasitized by *Anacanthorus spathulatus* (Monogenea: Dactylogiridae) in fish farm in the Peruvian Amazon. International Aquatic Research, v.6, p.251-255, 2014.

VELASCO, M.; SINDEAUX NETO, J.L.; VIDEIRA, M.; NASCIMENTO, L; GONÇALVES, E.C.; MATOS, E. *Kudoa amazonica* n. sp. (Myxozoa; Multivalvulida), a parasite of the esophageal musculature of the freshwater catfish, *Hypophthalmus marginatus* (Siluriformes: Pimelodidae), from a river of the Amazon region. Microbial Pathogenesis, v.130, p.247-252, 2019.

YANONG, R.P.E. Necropsy techniques for fish. Seminars in Avian and Exotic Pet Medicine, v.12, n.2. p.89-105, 2003.